

CASE REPORT



Biological restoration: A solution for restoring teeth with coronal fractures in young patients

Vanessa Torraca Peraro Vaz¹, Cristina Dupim Presoto¹, André Gustavo Paleari², Fernando Mandarino³, André Marcelo Peruchi Minto⁴, Osmir Batista de Oliveira Junior⁵, Marcelo Ferrarezi de Andrade⁵

¹Department of Restorative Dentistry, Araraquara Dental School, UNESP – Univ Estadual Paulista, Araraquara, SP, Brazil, ²Department of Dental Materials and Prosthodontics, Araraquara Dental School, UNESP-Univ Estadual Paulista, Araraquara, SP, Brazil, ³Department of Restorative Dentistry, Ribeirão Preto Dental School, University of São Paulo – USP, Ribeirão Preto, SP, Brazil, ⁴Department of Restorative Dentistry, University of Franca-Unifran, Franca, SP, Brazil, ⁵Department of Restorative Dentistry, Araraquara Dental School, UNESP-Univ Estadual Paulista, Araraquara, SP, Brazil

Keywords:

Biological restoration, dental trauma, fracture, maxillary central incisors

Correspondence:

Vanessa Torraca Peraro Vaz, Araraquara Dental School, Rua Humaitá 1680 CEP 14801-903, Araraquara, SP, Brazil. Phone: 55 16 3301-6393, Email: vanessatpvaz@yahoo.com.br

Received October 19, 2014;

Accepted January 03, 2015

doi: 10.15713/ins.sjod.21

How to cite the article:

Vaz VT, Presoto CD, Paleari AG, Mandarino F, Minto AM, Junior OB, Andrade MF. Biological restoration: A solution for restoring teeth with coronal fractures in young patients. *Sci J Dent* 2015;37-41.

Abstract

The “biological restoration” is an excellent technique for reconstruction in young traumatized teeth, which is used as intra-root reinforcement an extracted natural tooth. This article reports a case where an 11-year-old patient had his upper incisors affected by fractures from trauma. Due to the young age of the patient, the absence of the natural tooth fragment, the major structural loss and its high degree of anxiety, it was chosen to perform the treatment by this restorative technique that uses the “biological restoration” in addition to intra-root pins in an adjacent central incisor.

Introduction

Nowadays, traumatic dental injury has been the subject of many researches since its incidence is great among children and teenagers. It is shown that dental trauma corresponds to 18% of all injuries occurred in children at preschool age.^[1] According to Tavano *et al.*, 2009,^[2] almost 79% of children between 9 and 14 years have suffered some type of dental injury. This fact is related to the practice of sports and leisure activities, functional and psychological problems.^[3]

The maxillary central incisors are the teeth most commonly affected and involved in trauma.^[3-5] Several clinical options may be presented to reconstruct the smile of these patients affected by traumatic dental injuries. In recent decades, dentistry has shown many scientific and technological advances in relation to restorative materials. However, studies indicate that there is not more effective than the dental element.^[6,7] Therefore, several

authors suggest the use of natural teeth fragments as a restorative option to traumatized anterior teeth or the combination of these fragments with other restorative techniques.^[2,8,9]

The homogenous bonding, a situation in which the dental fragment can be bonded to the remaining tooth, consists in a simple and fast technique, with excellent cosmetic results.^[6,8,10] On the other hand, when the fragment is not present or it is not in a good condition, there is a possibility to use a teeth obtained from a human teeth bank, technique known as “biological restoration,” which is more suitable for large reconstructions.^[2,8,10] The esthetic result of these restorations is quite satisfactory because the color and anatomical details are more natural than those of artificial teeth.

This article describes a clinical case of an 11-year-old patient who suffered a dental injury caused by trauma in the maxillary anterior incisors. It was performed an association among the

biological restoration technique, fiberglass pin and the coronal restoration with direct composite resin.

Case Report

A male patient, 11-year-old, was referred to the Post-graduate Clinic of Restorative Dentistry, Araraquara Dental School-UNESP, with multiple dental fractures resulting from a fall during school playtime.

At the first appointment, during the clinical examination was diagnosed coronal fracture of great extension of the maxillary central incisors and the right upper lateral incisor [Figure 1]. Radiographic examination showed that the central incisors had been treated endodontically, with the apex of the right central incisor separated from the root by an oblique fracture [Figure 2]. The patient's mother reported that he had been attended by the pediatric dentistry clinic immediately after the accident.

Because of the young age of the patient, the absence of fragments of natural elements and the endodontic anatomy of the right central incisor, it was used a biological pin, once beyond the great extension of the fracture, the canal was wide enough to perform this

technique. On the left central incisor was used only a prefabricated fiberglass pin as reinforcement because there was enough remaining coronary, and subsequently both were reconstructed with light-cured resin [Figure 3]. It is very common in cases of tooth fractures a great anxiety for the solution of the problem by both the patient and his parents, once it is a widely aesthetic region.

Thus, after explaining to his mother the advantages and disadvantages of the technique, the impression was performed to obtain a model on which the diagnostic wax-up was carried out. The waxing led to the production of a silicone guide, which enabled the construction of direct light-cured resin restoration in the fractured elements. For the selection and adaptation of the tooth that was used as biological retainer to right central incisor was necessary preparation and shaping of the canal, as described below. Two-thirds of Gutta-percha was removed from the root canal with Gates Glidden drill, considering the working length reported in radiographic examination. Afterwards, the root canal was isolated with petroleum jelly to allow the impression with acrylic resin [Figure 4]. After the polymerization of acrylic resin, a

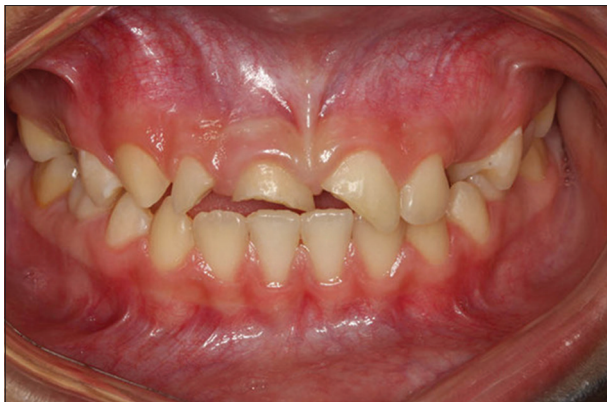

Figure 1: Coronal fracture of the anterior teeth

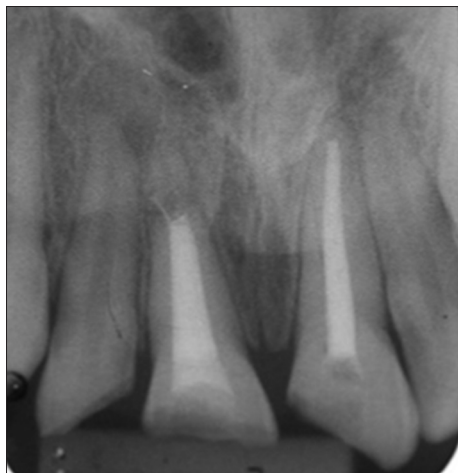

Figure 2: Initial radiograph

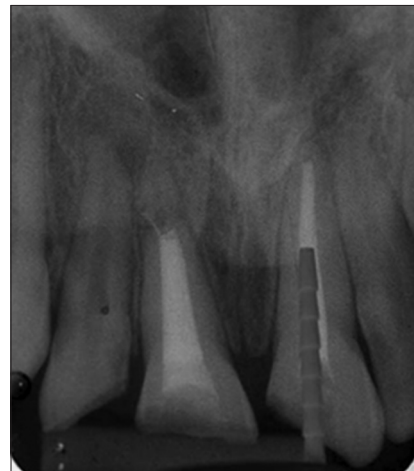

Figure 3: Selection of prefabricated fiberglass pin used in the left central incisor

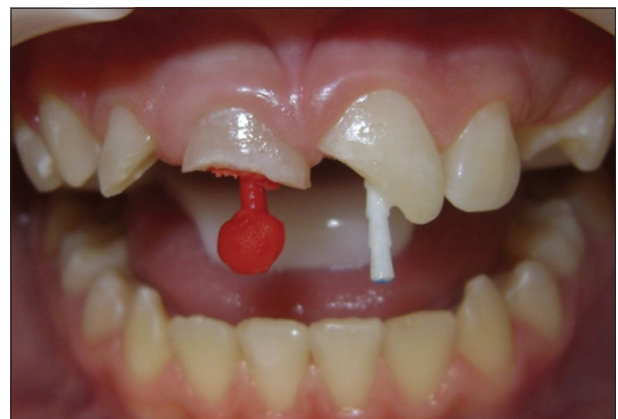


Figure 4: Intra-root impression with acrylic resin (right central incisor) and cementation of a prefabricated fiberglass pin

molding with polyvinyl siloxane (Elite[®] HD+-Zhermack-Italy) was performed to obtain a working cast.

A central incisor was selected in a human teeth bank, within a similar color of the remaining substrate and favorable dimensions for the chosen technique. The tooth was properly prepared to give access to the pulp chamber for internal cleaning with endodontic files and irrigation with 1% sodium hypochlorite. The remaining coronal portion was kept intact, and only $\frac{1}{3}$ of the cervical root portion was adapted to the root canal replicated on the cast [Figure 5]. Subsequently, the tooth was autoclaved at 121°C for 15 min to ensure biosafety standards.^[10]

In the second and final session, a gingival retraction cord Pro Retract1 female genital mutilation was inserted to assist the restorations procedures. The biological pin was conditioned with 37% phosphoric acid, washed and dried with paper towels, followed by adhesive system (Adper[™] Scotchbond[™] Multi-Purpose-3M ESPE, St Paul, USA) according to the manufacturer's instructions. The adhesive system was then cured with high-intensity light-emitting diode (Bluephase-Ivoclar Vivadent, Schaan-Lienchenstein) for 40 s. Once the root canal of the right central incisor was prepared, this was washed with 2% chlorhexidine. The biological pin was then inserted and cemented together with a prefabricated fiberglass pin (reforpost n.1, Angelus) [Figure 6]. This procedure had the purpose of strengthening the lingual and internal portions of the incisor used, which have been removed during their preparation, besides reducing the amount of cement into the root canal, since the biological pin does not fully completed the prepared root canal to receive it. The cement used was syringe system (SET PP) (SDI-Australia), which is a self-etch, dual-cure resin cement with good adhesion characteristics to both tooth structure as the fiber post. After adjustment of the biological pin-fiber pin to root canal with the selected cement, the polymerization was carried out with the same device described above. Likewise, the left central incisor received a prefabricated fiberglass pin (reforpost n.2, Angelus) to aid the retention of restorative composite resin. Only then began the reconstruction of dental elements with the aid of silicone guide, using incremental insertion technique of light cure resin IPS Empress Direct (Ivoclar), which is a Nano

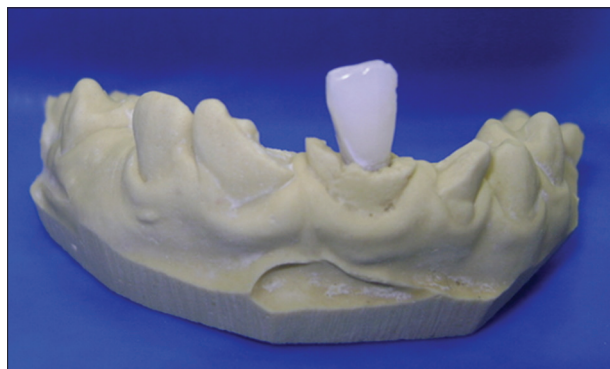

Figure 5: Teeth from human teeth bank adapted to the root canal of the central incisor replicated on the master cast

Hybrid composite restoration extremely aesthetic and easy to handle [Figure 7].

After the end of the restorations, a polishing was performed [Figure 8]. Instructions were given to the patient and their

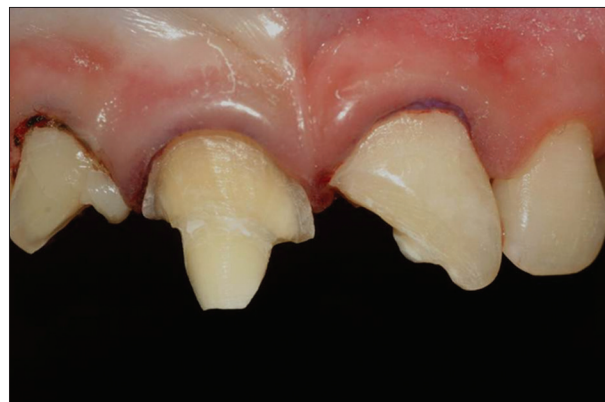

Figure 6: Biological pin inserted and cemented on right central incisor

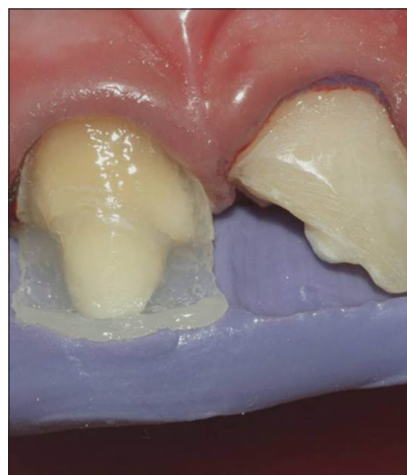

Figure 7: Reconstruction of central incisors using a silicone guide and light cure composite resin

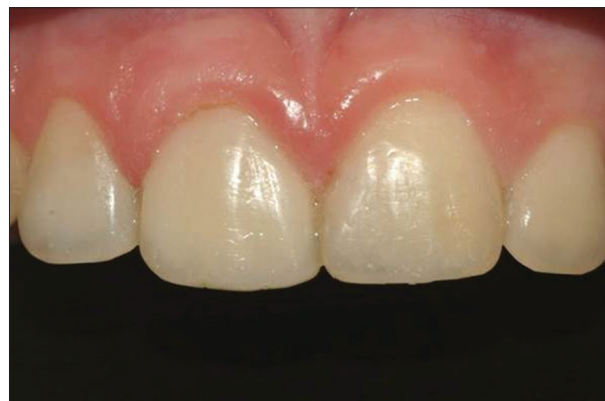

Figure 8: Clinical case after the end of the treatment

parents regarding the care to be taken for periodic maintenance of restorations.

Discussion

When the dentist considers the maximum aesthetics with minimal tooth reduction, the Result is an aesthetic and conservative treatment, maintaining the integrity of the remaining tooth structure. Thus, based on these concepts, it is known that a trauma in a highly aesthetic region, such as the central incisors, may result in impacts on the quality of life of an individual, such as behavioral changes in social relationships, low self-esteem and may lead to depression. Careful attention should be given to this problem, which is a great challenge in the modern restorative dentistry.^[5,11,12]

Due to fracture of maxillary central incisors, some treatments may be suggested, such as removal of the fragment, followed by restoration,^[13] allogeneic collage,^[2,6,8,13-16] increased clinical crown,^[13,17] orthodontic extrusion (with or without gingivoplasty),^[13] extraction, followed by implant and/or conventional fixed prostheses.^[13,17]

In a young patient, some factors must be considered, such as occlusion, hygiene, treatment time, incomplete bone growth and tooth eruption, longevity, need to change the restoration over time.^[13]

The allogeneic collage technique is the preferred among clinicians since that returns the function and esthetics of the element with much ease, convenience and speed due to the use of part of the dental element.^[1,6,8,14-16] However, when the fragment is not presented in suitable conditions, other techniques must be chosen. The use of extracted teeth, also called biological restoration is a viable alternative for the rehabilitation of the dental element.^[2,7,8,10,14-16,18-20] Some clinical research,^[2,10,18] demonstrated that the use of extracted teeth for dental reconstruction of elements with significant coronary losses allows better distribution of occlusal forces and still have a satisfactory cosmetic result. In these researches,^[2,10,18] the authors present advantages such as the absence of dentin stress; preserve the inner dentin of the root canal; exhibit biocompatibility and adaptation in the duct configuration, providing better resistance and retention of these pins when compared with other materials, exhibit similar resilience to natural tooth and provide excellent adhesion to tooth structure and composite resin.^[7,10,19,20]

However, some disadvantages can be presented as the difficulty of finding an extracted tooth with the color and the ideal format for the tooth to be restored, the patient may not accept a tooth of another patient, the technique is more sensitive and dehydration of the element or fragment, caused by handling and sterilization, can negatively affect the adherence to the bonding agent.^[2,10,19,20]

With the great evolution of dental adhesive materials and composite resins, highly resistant and esthetic, the biological restoration technique can be safely used, once after cementation of the biological pin to the remaining tooth structure, forms a Mono Block system between the cement and tooth structure,^[2,10,16]

which help distribute the occlusal forces during mastication.^[21] However, it is fundamental to avoid traumatic occlusal stress with the purpose of to prolong the clinical success.^[13]

In the case reported in this article, the selection of restorative technique was based on patient age, in an advanced state of anxiety of the patient and his charge, and low financial level of the same. Due to the young age of the patient, the extent of the root canal was a key factor for the use of a natural tooth as pin reinforcement.

Some authors, as Corrêa-Faria *et al.*, 2010^[10] in their research about biological pins, chose to reduce the root of the extracted tooth and then relined it with light-curing resin for better adaptation in the root canal. In this work, this reduction was not performed because it was preferred to preserve the root structure, since the canal where was adapted the pin was already wide, once was a young tooth. Thus the amount of cement within the canal was reduced thereby facilitating the adhesion and strength of the restoration, forming a mixed block of cement/resin/cementum.

Obtaining an enhanced natural tooth with a prefabricated fiberglass pin, it was possible to restore the function and aesthetics of the fractured element in a few treatment sessions, with low cost and comfort to the patient. Bonilla, 2001^[22] conducted a study comparing some types of intra-canal nucleus and resistance to transverse fracture of the largely destroyed roots. The author observed that the resistance to fracture of largely destroyed roots, rebuilt with biological pin was 30% higher than the weakened and reconstructed roots only with cast metal core or reconstructed with composite resin and cast metal core.

As in the work of Corrêa-Faria *et al.*, 2010,^[10] the result obtained with the association between crowns and biological pins offers excellent aesthetic, functional and psychosocial outcome, which justifies the use of this technique to achieve morfofuncional recovery of widely destroyed teeth. Botelho *et al.*, 2012 [18] stated that this is a viable treatment option. However, further studies are needed to assess the behavior of adhesion and resistance over time to better understand the benefits of the technique.

Conclusion

Considering the reported clinical case, it can be observed that the "Biological restoration" technique may be an important alternative to rehabilitate dental elements with great coronary destruction, to be a safe, easy handling, fast and with excellent aesthetic results.

References

1. Glendor U. Epidemiology of traumatic dental injuries – A 12 year review of the literature. *Dent Traumatol* 2008;24:603-11.
2. Tavano KT, Botelho AM, Motta TP, Paes TM. 'Biological restoration': Total crown anterior. *Dent Traumatol* 2009;25:535-40.
3. Piovesan C, Guedes RS, Casagrande L, Ardenghi TM. Socioeconomic and clinical factors associated with traumatic

- dental injuries in Brazilian preschool children. *Braz Oral Res* 2012;26:464-70.
4. Robson F, Ramos-Jorge ML, Bendo CB, Vale MP, Paiva SM, Pordeus IA. Prevalence and determining factors of traumatic injuries to primary teeth in preschool children. *Dent Traumatol* 2009;25:118-22.
 5. David J, Astrøm AN, Wang NJ. Factors associated with traumatic dental injuries among 12-year-old schoolchildren in South India. *Dent Traumatol* 2009;25:500-5.
 6. Busato AL, Loguercio AD, Barbosa AN, Sanseverino Mdo C, Macedo RP, Baldissera RA. Biological restorations using tooth fragments. *Am J Dent* 1998;11:46-9.
 7. Galindo VA, Nogueira JS, Yamasaki E, Kós Miranda D. Biological posts and natural crowns bonding-alternatives for anterior primary teeth restoration. *J Bras Odontopediatr Odontol Bebe* 2000;16:513-20.
 8. Demarco FF, de Moura FR, Tarquinio SB, Lima FG. Reattachment using a fragment from an extracted tooth to treat complicated coronal fracture. *Dent Traumatol* 2008;24:257-61.
 9. Nogueira Filho Gda R, Machion L, Teixeira FB, Pimenta LA, Sallum EA. Reattachment of an autogenous tooth fragment in a fracture with biologic width violation: A case report. *Quintessence Int* 2002;33:181-4.
 10. Corrêa-Faria P, Alcântara CE, Caldas-Diniz MV, Botelho AM, Tavano KT. "Biological restoration": Root canal and coronal reconstruction. *J Esthet Restor Dent* 2010;22:168-77.
 11. Cortes MI, Marcenes W, Sheiham A. Impact of traumatic injuries to the permanent teeth on the oral health-related quality of life in 12-14-year-old children. *Community Dent Oral Epidemiol* 2002;30:193-8.
 12. Baldwin DC. Appearance and aesthetics in oral health. *Community Dent Oral Epidemiol* 1980;8:244-56.
 13. Krishna A, Malur MH, Swapna DV, Benjamin S, Deepak CA. Traumatic dental injury-an enigma for adolescents: A series of case reports. *Case Rep Dent* 2012;2012:756526.
 14. Reis A, Loguercio AD, Kraul A, Matson E. Reattachment of fractured teeth: A review of literature regarding techniques and materials. *Oper Dent* 2004;29:226-33.
 15. Gonzales PA, Busato AL. Restaurações biológicas com fragmentos dentários. *RBO* 1994;51:83-7.
 16. Macedo GV, Diaz PI, De O Fernandes CA, Ritter AV. Reattachment of anterior teeth fragments: A conservative approach. *J Esthet Restor Dent* 2008;20:5-18.
 17. Olsburgh S, Jacoby T, Krejci I. Crown fractures in the permanent dentition: Pulpal and restorative considerations. *Dent Traumatol* 2002;18:103-15.
 18. Botelho AM, Tavano KT, Correa-Faria P, Morato LN, Viana MR. Esthetic-functional recovery of permanent posterior tooth using autogenous biological restoration. *J Indian Soc Pedod Prev Dent* 2012;30:333-6.
 19. Kaizer OB, Bonfante G, Pereira Filho LD, Reis KR, Lucas C. Utilization of biological posts to reconstruct weakened roots. *Rev Gaucha Odontol* 2008;56:7-13.
 20. Kaizer OB, Bonfante G, Pegoraro LF, Kaizer RO, Reis KR. Resistência à fratura de dentes tratados endodonticamente, reconstruídos com pinos de fibras de polietileno e com pinos biológicos. *Rev Gaucha Odontol* 2009;57:19-25.
 21. Andreasen FM, Norén JG, Andreasen JO, Engelhardt S, Lindh-Strömberg U. Long-term survival of fragment bonding in the treatment of fractured crowns: A multicenter clinical study. *Quintessence Int* 1995;26:669-81.
 22. Bonilla ME. Avaliação da resistência à fratura transversal de raízes amplamente destruídas reconstruídas com núcleos (Dissertação). Bauru: Universidade de São Paulo; 2001.